




Research Article

The Flavonoid Chrysin Protects against Testicular Apoptosis Induced by Torsion/Detorsion in Adult Rats

Ayda Roudi Rasht Abadi,¹ Linda Mohammadzadeh Boukani,² Majid Shokoohi ,³ Nasim Vaezi,⁴ Monireh Mahmoodi,⁵ Mehdi Gharekhani,³ Homa Mohseni Kouchesfahani ,¹ and Amir Afshin Khaki ⁶

¹Department of Animal Biology, Faculty of Biological Sciences, Kharazmi University, Tehran, Iran

²Student Research Committee, Tabriz University of Medical Sciences, Tabriz, Iran

³Clinical Research Development Unit of Tabriz Valiasr Hospital, Tabriz University of Medical Sciences, Tabriz, Iran

⁴Faculty of Veterinary Medicine, University of Tabriz, Tabriz, Iran

⁵Department of Biology, Faculty of Science, Arak University, Arak, Iran

⁶Department of Anatomical Sciences, School of Medicine, Tabriz University of Medical Sciences, Tabriz, Iran

Correspondence should be addressed to Majid Shokoohi; a.shokoohy@yahoo.com, Homa Mohseni Kouchesfahani; kouchesfehani@yahoo.com, and Amir Afshin Khaki; dr.aakhaki@yahoo.com

Received 17 November 2022; Revised 31 January 2023; Accepted 22 February 2023; Published 29 April 2023

Academic Editor: Vikas Kumar Roy

Copyright © 2023 Ayda Roudi Rasht Abadi et al. This is an open access article distributed under the Creative Commons Attribution License, which permits unrestricted use, distribution, and reproduction in any medium, provided the original work is properly cited.

In the present work, we examined the beneficial efficacy of chrysin as a natural flavonoid on testicular torsion/detorsion damages among adult male rats. Forty-eight male Wistar rats were randomly allocated into six groups: sham, torsion/detorsion (TD) group, TDC30 group in which TD process was applied and treated with chrysin (30 mg/kg), TDC50 group in which TD process was applied and treated with chrysin (50 mg/kg), HC30 group in which animals were treated with chrysin (30 mg/kg), and HC50 group in which rats were treated with chrysin (50 mg/kg). Serum samples were tested for testosterone, luteinizing hormone (LH), and follicle-stimulating hormone (FSH) levels. The sperm parameters, histopathological analysis, and expressions of apoptosis-related genes were examined among different groups. Superoxide dismutase (SOD), glutathione peroxidase (GPx), and malondialdehyde (MDA) levels in the testicles and serum were measured. Serum levels of SOD, GPx, FSH, LH, and “Bax” expression significantly increased in the TD group compared to the sham group ($P < 0.05$). Sperm parameters, serum testosterone level, Johnson’s scores, seminiferous tubule diameter, the height of the germinal epithelium (HE) measurements, and expression of “Bcl2” meaningfully decreased ($P < 0.05$). Administration of chrysin impeded ischemia/reperfusion damages in testis tissue and improved sperm quality. The result of our study indicates that treatment with chrysin can protect testis tissue from ischemia/reperfusion damages induced by TD procedure.

1. Introduction

Infertility is a global concern affecting 15% of husbands and wives worldwide [1]. Based on previous studies, male infertility rates might range from 2.5% to 12% in different countries [2]. Several reasons are responsible for male infertility, such as environmental factors, endocrinological problems, and physical and chemical injuries [3]. Semen analysis in suspected cases of male infertility can demonstrate the quality of the semen and fertility potential [4]. Some of the

underlying causes of poor semen quality are reported, including sperm motility disturbance, low sperm count (oligozoospermia), chromosomal, and hormonal abnormalities [5].

Twisting of the spermatic cord and testis results in testicular torsion, a dangerous urological emergency [6]. Testicular dysfunction and testicular necrosis result from torsion of the testis [7]. Surgery is the most acceptable treatment strategy for correcting testicular torsion at the earliest possible time [8]. Torsion of the testicles leads to blood interruption

TABLE 1: The sequences of the primers were used in the quantitative real-time PCR.

Gene	Significance	Forward primer (5'-3')	Backward primer (5'-3')
Bax	Apoptosis regulator	GGCGAATTGGAGATGAACTG	TTCTTCCAGATGGTGAGCGA
Bcl-2	Apoptosis regulator	CTTTGCAGAGATGTCCAGTCAG	GAACTCAAAGAAGGCCACAATC
GAPDH	Internal control	GCAGCTCCTTCGTTGCCGGT	CCCGCCCATGGTGTCCGTTCC

and causes ischemia [8]. During the ischemia stage, oxygen supply decreases and toxic metabolites increase which leads to germ cell death [9]. It is known that in the ischemia stage, hypoxanthine (an ATP breakdown product) is highly produced [10]. After the detorsion of twisted testes, in the reperfusion stage, hypoxanthine converts into dangerous free oxygen molecules such as superoxide anions, hydroxyl radicals, and peroxynitrite [10]. Accordingly, ischemia/reperfusion injury is the main pathological process that damages the testis during the torsion/detorsion process [11]. Oxidative stress is a detrimental condition introduced as an infertility prompting factor [1]. Scientists are in agreement about increasing ROS overproduction during oxidative stress [12]. This excessive production of ROS leads to sperm DNA damage, protein denaturation, and lipid peroxidation of the sperm membrane [13–15].

Chrysin (5,7-dihydroxyflavone) is a naturally occurring flavonoid in different plant species such as *Radix Scutellaria*, *Lactarius deliciosus*, and *Oroxylum indicum* [16, 17]. Numerous investigations have noted the ability of chrysin to neutralize free radicals [18, 19]. Furthermore, chrysin indicated other beneficial effects, such as anticancer and anti-inflammatory activities [17, 20]. Moreover, recent investigations have indicated the notable effects of chrysin treatment on male fertility, such as improvement of semen quality, boosting testosterone production, and enhancing testicular antioxidant defense [20, 21].

Accordingly, in the current study, we aimed to evaluate the beneficial effect of chrysin treatment in ischemia/reperfusion injury induced by testicular TD process in adult male rats, by investigating oxidative stress markers, histopathological changes, expression of apoptotic-related genes, and sperm quality and hormonal alternations.

2. Material and Methods

2.1. Study Design. In this study, 48 male Wistar albino rats with approximately 200 g weight were purchased from Razi Institute (Karaj, Iran). Before starting the experimental period, animals were housed for one week in the animal room (with a normal temperature of 25°C, 12 h/12 h light and dark cycle) for adaptation. The rats were randomly allocated into six groups (8 rats in each group): group 1 (sham group) in which only scrotal incision was performed, and the skin was immediately sutured without employing a torsion/detorsion procedure. In group 2 (torsion/detorsion group (TD group)), a surgical procedure was performed. The left testis of each rat was twisted 720° counterclockwise for 4 hours. After 4-hour torsion period, the left testis was rotated into normal condition (detorsion). In group 3 (TD30), the torsion process was applied, and animals were

treated with chrysin for the first time (oral administration of 30 mg/kg) 30 minutes before detorsion of the testis (detorsion), followed by daily administration of chrysin for two weeks. The next group (TD50) was almost the same as the previous group (TD30), and only the dose of the chrysin treatment (oral administration of 50 mg/kg) was different. In group 5 (HC30), in this group, healthy rats (without employing torsion/detorsion procedure) were treated with chrysin (oral administration of 30 mg/kg) for two weeks. In group 6 (HC50), similar to the previous group, healthy rats received chrysin with a 50 mg/kg dose.

2.2. Surgery Procedure. A combination of ketamine and xylazine was used to anesthetize the animals (100/10 mg/kg). Under the sterile condition, an abdominal incision was carried out, and the left testis was detected. Then, the left testis and spermatic cord were then turned 720 degrees counterclockwise. The left testis was maintained in torsion position for 4 hours by suturing the scrotum. After the torsion period (4hr), the sutures were opened, and the left testis was rotated into a normal position. After detorsion, rats were kept in the treatment period for two weeks. Animals were sedated, and blood samples were taken at the completion of the treatment period. Finally, testis tissue samples were collected.

2.3. Histological Evaluation. Testicular samples were located in Bouin's solution for two days. Then, samples were dehydrated and embedded in paraffin. Subsequently, paraffin-embedded samples were cut into 5 µm sections. Sections of testicular tissues were stained with hematoxylin and eosin (H&E) and then observed under a light microscope to analyze the tissues (Olympus CX310, Japan). Images were captured by using a digital camera (Olympus, Japan). Ten seminiferous tubules per slide were examined in order to determine the mean diameter of the seminiferous tubule (STD) and the thickness of the germinal epithelium (TE). According to Johnson's score, 50 seminiferous tubules were observed per section to analyze spermatogenesis. Each tubule was examined with a light microscope and was scored 1-10 according to the epithelial structures.

2.4. Determination of Testicular and Serum Oxidative Stress Markers. The malondialdehyde levels (MDA) were measured in serum samples by performing some procedures. First, a microtube containing 3.0 cm³ of glacial acetic acid and 0.20 cm³ of serum samples was combined. Next, 1% TBA (thiobarbituric acid) was added to 2% NaOH in a microtube. The microtube was located in boiling water for 15 minutes. After cooling the samples, the absorbance of the pink solution was measured using a spectrophotometer

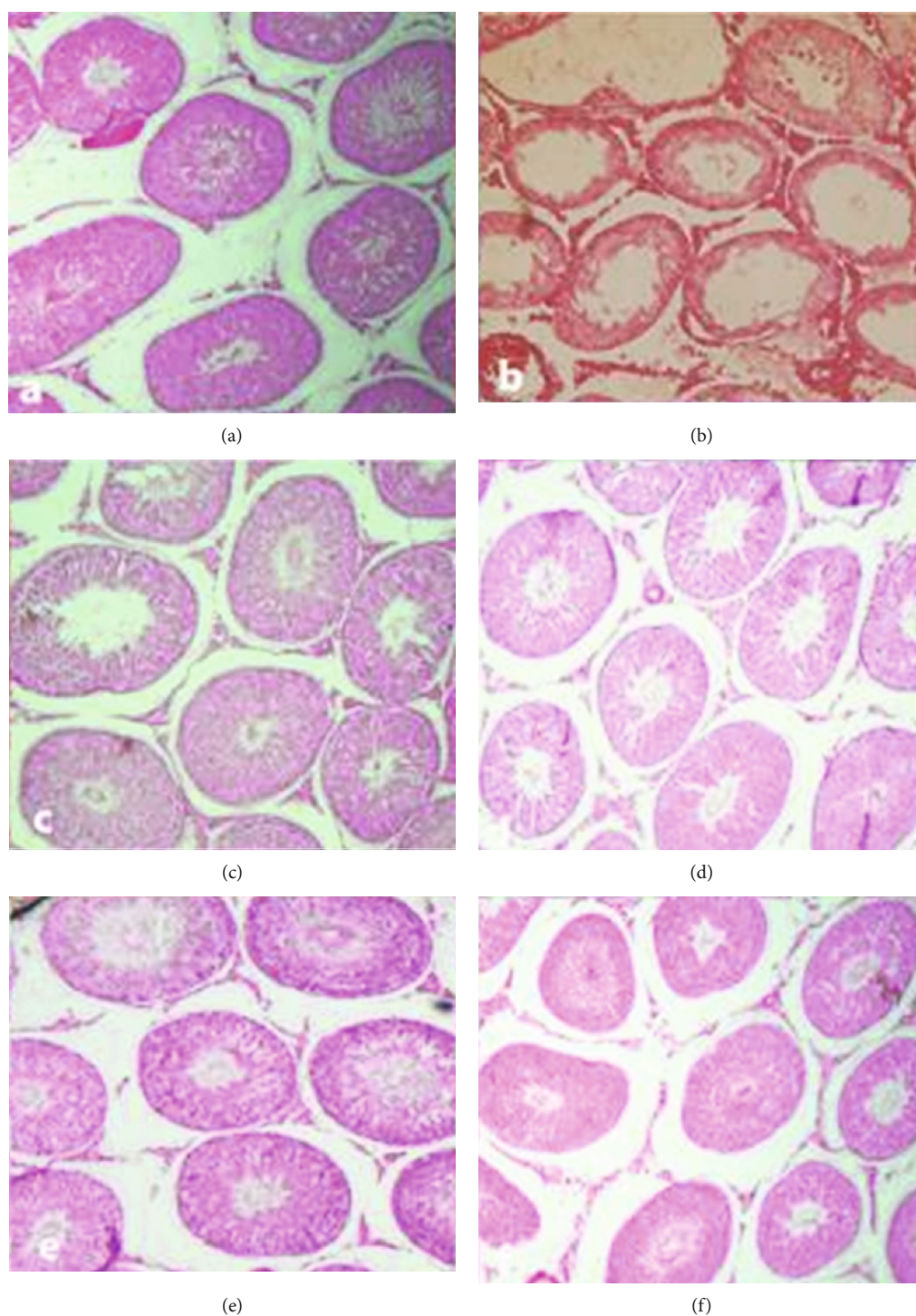


FIGURE 1: Histopathological investigations of the testicular tissues with hematoxylin and eosin (H&E) staining: (a) sham group; (b) torsion/detorsion (TD) group; (c) in torsion/detorsion rats that received 30 mg/kg of chrysin (TDC30 group); (d) in torsion/detorsion rats that received 50 mg/kg of chrysin (TDC50 group); (e, f) normal rats that received 30 mg/kg and 50 mg/kg of chrysin (HC30 and HC50 groups), H&E staining ($\times 100$).

(Biospect, USA) at a wavelength of 532 nm. Tetrabutylammonium salt was used to obtain the calibration curve for the standard solutions of MDA (Sigma-Aldrich, USA). According to the manufacturer's instructions, the levels of "superoxide dismutase" (SOD) and "glutathione peroxidase" (GPx) were determined using commercial kits from Sigma,

USA, and then read using the ELISA method by Ransod and Randox. To analyze tissue oxidative stress markers, testicular tissues were homogenized with a homogenizer. Ice-cold potassium phosphate buffer was used to prepare a 20% *w/v* homogenate. After the centrifuging at 4000 rpm for 15 min, the supernatant was obtained and used for

TABLE 2: Comparison of the mean Johnson's score, STD, and HE in testicular samples of different groups.

Groups	Johnson's score Mean \pm SD	STD Mean \pm SD	HE Mean \pm SD
Sham	9.117 \pm 0.11	259.03 \pm 6.28	68.08 \pm 2.33
TD	4.171 \pm 0.19*	133.28 \pm 1.88**	30.26 \pm 2.91**
TDC30	7.151 \pm 0.21#	202.33 \pm 4.39#	51.23 \pm 2.22#
TDC50	7.091 \pm 0.31#	203.03 \pm 3.31#	50.33 \pm 2.44#
HC30	9.185 \pm 0.12#	252.21 \pm 6.11##	68.15 \pm 2.45##
HC50	9.260 \pm 0.17##	260.03 \pm 4.39##	69.16 \pm 2.76##

Groups: sham; TD: torsion/detorsion; TDC30: rats underwent torsion/detorsion procedure with 30 mg/kg chrysin treatment; TDC50: rats underwent torsion/detorsion procedure with 50 mg/kg chrysin treatment; HC30: normal rats were treated with 30 mg/kg chrysin treatment; HC50: normal rats were treated with 50 mg/kg chrysin treatment. All data are showed as mean \pm SD. The asterisk (*) indicates significant difference with the sham group, and the symbol # shows the significant difference with the TD group. * $P < 0.05$, ** $P < 0.01$, # $P < 0.05$, and ## $P < 0.01$. STD: seminiferous tubule diameter; HE: height of epithelium.

measuring "superoxide dismutase" (SOD), "glutathione peroxidase" (GPx), and "malondialdehyde" (MDA). Measurements of SOD and GPx were carried out using an ELISA reader based on the manufacturer's protocols (Randox, UK). As an indicator of oxidative stress, MDA is the main metabolite of lipid peroxidation. The MDA level was assessed using TBA-TCA-HCL solutions (trichloroacetic acid, thiobarbituric acid, and hydrogen chloride). Two milliliters of mentioned solution was added to 1 ml of homogenized tissue. After boiling (45 min) and cooling, the solution was centrifuged. To measure the MDA level based on the reaction of MDA with TBA, a spectrophotometer was used to read the absorption at 535.

2.5. Measurement of Serum Hormone Levels. Blood samples were centrifuged at 5000 for 5 minutes. Then, serum samples were isolated and stored at -70°C . "Luteinizing hormone" (Romero et al.), "follicle-stimulating hormone" (FSH), and "testosterone" concentrations in serum were measured using the ELISA technique according to manufacturer's protocols (Demeditec Diagnostics, Germany).

2.6. Quantitative Real-Time PCR (qRT-PCR). The expression of Bax and Bcl2 genes in different groups was investigated by qRT-PCR. Total RNA extraction was performed using TRIzol (Invitrogen, Paisley, UK) from collected samples, according to the manufacturer protocol. A NanoDrop 1000 device carried out quantification of isolated RNA. Complementary DNA (cDNA) was synthesized using Thermo Scientific cDNA synthesis kit (Thermo Scientific, EU). The qRT-PCR assay was performed using a SYBER Green RT-PCR kit with specific primers in a 48-well StepOne Real-Time PCR System (Applied Biosystems, UK). The primer sequences are listed in Table 1. The PCR program included four steps: one cycle at 95°C for 10 min, 40 cycles at 95°C for 15 sec, 58°C for 30 sec, and 72°C for 30 sec and one cycle of 95°C for 15 sec, 60°C for 1 min, and 95°C for 25 sec. Analysis of genetic information in different groups was done

using Δct method based on the house keeping gene (GAPDH) and normalized with the control group.

2.7. Sperm Parameters. The left testis and epididymis were dissected and weighted with digital scales. The left epididymis was chopped using sterile scissors for exiting sperms. Semen was diluted in 1 ml of PBS. Sperm motility was measured by considering motile and nonmotile sperm by assessing total of sperm in five fields of view under the microscope. Sperm count was performed using a Neubauer slide according to the standard protocol. Sperm morphology was investigated following preparing the smears of spermatozoa and staining with H&E. The mean percentage of morphologically normal spermatozoa was calculated following counting 100 spermatozoa in each slide.

2.7.1. Immunohistochemistry. The protein expression of Bax and Bcl-2 was detected by a commercial immunoperoxidase kit (Santa Cruz, Germany) following the kit's guidelines. Twenty seminiferous tubules were investigated in each of the three sections of each slide that were 5 m thick and used for IHC staining. The protein expression investigation protocol included the following procedures: (1) the natural peroxidase activity was inhibited using 3% H_2O_2 for 20 minutes; (2) the testis tissue sections were rinsed through PBS for five minutes; (3) antigen retrieval was performed using the boiling method that the slides were put in 0.01 M sodium citrate buffer (pH = 6.0) for 20 minutes; (4) the tissue samples were rinsed by PBS solution for five minutes; (5) the cell membranes' permeance was performed by 0.3% Triton; sections were then placed in an incubator for 45 minutes; (6) tissue sections were then placed in an incubator with a 10% normal goat serum and PBS combination for 30 minutes, and slides were treated with Bcl-2 primary polyclonal antibodies (Santa Cruz, sc-783), Bax primary polyclonal antibodies (Santa Cruz, sc-493), and "GAPDH primary polyclonal antibodies" (Santa Cruz, sc-25778) at a dilution ratio of 1 : 100 at 4°C in a dark environment overnight; (7) testis tissue samples were rinsed three times with PBS for five minutes, after which the FITC-conjugated IgG (the second antibody) was added to the solutions and incubated for 90 minutes at 37°C in the dark; (8) the PBS was used to clean all of the tissue slides (four times for five minutes in each wash), and afterwards, nuclei were initially removed by washing with propidium iodide (Yuan et al.); (9) following which, tissue sections were rinsed twice with PBS (each wash taking five minutes); and (10) slides were evaluated using an "Olympus fluorescence microscope" (BX51, Japan). The procedure for staining the negative control was the same as in other experiments. According to research by Banerjee and Chaturvedi, the ImageJ software (NIH, USA) was used to calculate the average intensity of the proteins Bax and Bcl-2 ($n = 10$ for each group). [22, 23].

2.7.2. Apoptosis Detection in Testicular Tissue (TUNEL Assay). We used the "TUNEL assay kit (In Situ Cell Death Detection Kit, Roche, Germany)" to determine each sample's testicular germ cells' death rate. Briefly, after deparaffinization and dehydration, PBS (Sigma-Aldrich, Germany)

TABLE 3: Testicular and serum levels of SOD, GPx, and MDA in all groups of the study.

Groups	MDA (mean \pm SD)		SOD (mean \pm SD)		GPx (mean \pm SD)	
	Testis	Serum	Testis	Serum	Testis	Serum
Sham	0/50 \pm 0/03	0.78 \pm 0.086	1/77 \pm 0/04	1.70 \pm 0.02	21/84 \pm 0/77	21.30 \pm 0.36
TD	1/99 \pm 0/019**	2.04 \pm 0.015***	0/72 \pm 0/16*	0.69 \pm 0.01*	8/71 \pm 0/63***	8.74 \pm 0.54***
TDC30	0/75 \pm 0/031 [#]	0.80 \pm 0.017 ^{##}	1/23 \pm 0/24 [#]	1.34 \pm 0.03 [#]	16/20 \pm 0/89 ^{##}	18.52 \pm 0.53 ^{##}
TDC50	0/76 \pm 0/021 [#]	0.78 \pm 0.086 ^{##}	1/10 \pm 0/13 [#]	1.19 \pm 0.03 [#]	18/24 \pm 0/69 ^{##}	16.67 \pm 0.89 ^{##}
HC30	0/61 \pm 0/020 ^{##}	0.65 \pm .036 ^{##}	1/20 \pm 0/23 [#]	1.83 \pm 0.06 [#]	21/72 \pm 0/74 ^{###}	22.74 \pm 0.64 ^{###}
HC50	0/53 \pm 0/012 ^{##}	0.50 \pm 0.019 ^{##}	1/73 \pm 0/24 [#]	1.81 \pm 0.01 [#]	21/81 \pm 0/31 ^{###}	21.87 \pm 0.26 ^{###}

Groups: sham; TD: torsion/detorsion; TDC30: rats underwent torsion/detorsion procedure with 30 mg/kg chrysin treatment; TDC50: rats underwent torsion/detorsion procedure with 50 mg/kg chrysin treatment; HC30: normal rats were treated with 30 mg/kg chrysin treatment; HC50: normal rats were treated with 50 mg/kg chrysin treatment. All data are showed as mean \pm SD. The asterisk (*) indicates significant difference with the sham group, and the symbol # shows the significant difference with the TD group. * P < 0.05, ** P < 0.01, *** P < 0.001, # P < 0.05, ## P < 0.01, and ### P < 0.001. MDA: malondialdehyde; SOD: superoxide dismutase; GPx: glutathione peroxidase.

TABLE 4: Relative expression of Bax and Bcl-2 genes in all groups of the study.

Groups	Bax	Bcl-2
Sham	0/31 \pm 0/01	1/22 \pm 0/02
TD	1/50 \pm 0/05**	0/42 \pm 0/01**
TDC30	0/53 \pm 0/04 [#]	1/15 \pm 0/03 ^{##}
TDC50	0/57 \pm 0/03 [#]	1/09 \pm 0/02 ^{##}
HC30	0/36 \pm 0/02 ^{##}	1/22 \pm 0/01 ^{##}
HC50	0/33 \pm 0/02 ^{##}	1/23 \pm 0/01 ^{##}

Groups: sham; TD: torsion/detorsion; TDC30: rats underwent torsion/detorsion procedure with 30 mg/kg chrysin treatment; TDC50: rats underwent torsion/detorsion procedure with 50 mg/kg chrysin treatment; HC30: normal rats were treated with 30 mg/kg chrysin treatment; HC50: normal rats were treated with 50 mg/kg chrysin treatment. All data are showed as mean \pm SD. Relative expression levels were normalized to the endogenous control gene (GAPDH). The asterisk (*) indicates significant difference with the sham group, and the symbol # shows the significant difference with the TD group. * P < 0.05, ** P < 0.01, # P < 0.05, and ## P < 0.01.

was used to clean all testicular sections before they were placed in an incubator with proteinase K (15 g/ml) for 20 minutes at 37°C. All the tissue slides were then combined with the permeation solution for 10 minutes and washed with PBS. Each testis tissue slide was then treated with 50 ml of TUNEL dye solution for an hour at a temperature of 37°C. Finally, after cleaning the testicular sections with PBS, the tissue sections were examined under “An Olympus fluorescent microscope (BX51, Japan)”. DAPI was used as a counterstain on the cell nuclei. In a chance area of the microscope, the number of TUNEL-positive cells in testicular slices was analyzed. The apoptosis index was calculated as the ratio of TUNEL-positive cells to total cells. Negative controls were stained in accordance with past findings [22], and testicular samples lacked any nonspecifically labeled cells.

2.8. Statistical Analysis. Statistical analysis was performed using SPSS, version 19. The current study indicated all the results as mean \pm SD (standard division). Differences between the six groups were analyzed with one-way ANOVA followed by the Tukey test. P value < 0.05 was considered a significant level.

3. Results

3.1. Histopathological Evaluations. Histopathological analysis in different groups showed that Johnson’s scores were significantly diminished in the TD group compared to the sham ($P = 0.001$) (Figure 1). Additionally, compared to the sham group, testes in the TD group had less STD and HE and more severe lesions in the seminiferous tubules. Histological samples of the TDC30 and TDC50 groups indicated less severe pathological changes compared to the TD group ($P = 0.001$). Results of Johnson’s score, STD, and HE levels in different groups are shown in Table 2. No significant differences were found in Johnson’s score, STD, and HE levels in healthy groups that treated with 30 and 50 mg/kg of chrysin compared to the sham group ($P > 0.05$) (Table 2).

3.2. The Oxidative Stress Marker Levels in Serum and Testis Tissue. The level of testicular MDA in the TD group was significantly more than the sham group increased ($P < 0.01$), whereas the levels of SOD and GPx meaningfully decreased ($P < 0.05$). In both TDC30 and TDC50 groups, the testicular levels of MDA decreased, and the levels of the SOD and GPx interestingly increased ($P < 0.05$) (Table 3). Chrysin treatment with 30 mg/kg was more effective than 50 mg/kg in improving antioxidative conditions in testis tissue. The differences in MDA, SOD, and GPx levels in the HC30 and HC50 groups compared to the sham group were not significant ($P > 0.05$) (Table 3). The comparison of serum levels of MDA between the treated (TDC30 and TDC50) groups and TD groups showed a significant decrease in the levels of MDA in groups treated with chrysin ($P < 0.01$). The serum level of SOD in the TDC30 and TDC50 groups was remarkably increased compared to either TD or sham groups ($P < 0.05$). The serum levels of GPx were significantly reduced in all experimental TD groups compared to the sham group (Table 3). The levels of GPx were elevated in the TDC30 and TDC50 groups compared with the TD group ($P < 0.01$). Besides, the concentration of GPx was higher in the HC30 and HC50 groups compared with the sham group. Also, chrysin treatment with 30 mg/kg was more effective than 50 mg/kg in improving antioxidative conditions in serum oxidative stress markers (Table 3).

TABLE 5: Comparison of the testicular weight and sperm parameters in different groups of the study.

Groups	Testicular weight (g)	Concentration $\times 10^5$ /ml	Normal morphology	Normal motility
Sham	1/32 \pm 0/042	29/31 \pm 1/32		64/32% \pm 3/31
TD	0/46 \pm 0/030**	3/54 \pm 2/09***		12/00% \pm 5/70***
TDC30	0/98 \pm 0/045 [#]	23/32 \pm 1/12 ^{###}		56/25% \pm 7/50 ^{##}
TDC50	0/87 \pm 0/035 [#]	23/16 \pm 0/21 ^{###}		61/67% \pm 8.75 ^{###}
HC30	1/31 \pm 0/031 ^{##}	28/43 \pm 1/01 ^{###}		63/12% \pm 3/02 ^{###}
HC50	1/34 \pm 0/031 ^{##}	29/23 \pm 1/21 ^{###}		66/12% \pm 2/71 ^{###}

Groups: sham; TD: torsion/detorsion; TDC30: rats underwent torsion/detorsion procedure with 30 mg/kg chrysin treatment; TDC50: rats underwent torsion/detorsion procedure with 50 mg/kg chrysin treatment; HC30: normal rats were treated with 30 mg/kg chrysin treatment; HC50: normal rats were treated with 50 mg/kg chrysin treatment. All data are showed as mean \pm SD. The asterisk (*) indicates significant difference with the sham group, and the symbol # shows the significant difference with the TD group. * $P < 0.05$, ** $P < 0.01$, *** $P < 0.001$, # $P < 0.05$, ## $P < 0.01$, and ### $P < 0.001$.

TABLE 6: Comparison of serum FSH, LH, and testosterone levels in different groups of the study.

Groups	FSH (mIU/ml)	LH (mIU/ml)	Testosterone (ng/ml)
Sham	1/67 \pm 0/42	1/49 \pm 0/36	4/81 \pm 0/34
TD	3/77 \pm 0/11**	2/79 \pm 0/11**	1/87 \pm 0/35**
TDC30	2/13 \pm 0/82 [#]	1/94 \pm 0/50 [#]	3/41 \pm 1/3 [#]
TDC50	2/38 \pm 0/55 [#]	2/44 \pm 0/80 [#]	3/13 \pm 2/36 [#]
HC30	1/56 \pm 0/44 ^{##}	1/28 \pm 0/15 ^{##}	4/91 \pm 0/86 ^{##}
HC50	1/95 \pm 0/10 ^{##}	1/30 \pm 0/15 ^{##}	5/17 \pm 0/82 ^{##}

Groups: sham; TD: torsion/detorsion; TDC30: rats underwent torsion/detorsion procedure with 30 mg/kg chrysin treatment; TDC50: rats underwent torsion/detorsion procedure with 50 mg/kg chrysin treatment; HC30: normal rats were treated with 30 mg/kg chrysin treatment; HC50: normal rats were treated with 50 mg/kg chrysin treatment. All data are showed as mean \pm SD. The asterisk (*) indicates significant difference with the sham group, and the symbol # shows the significant difference with the TD group. * $P < 0.05$, ** $P < 0.01$, # $P < 0.05$, and ## $P < 0.01$. FSH: follicle-stimulating hormone; LH: luteinizing hormone.

3.3. Apoptosis-Related Gene Expression. The expression of Bax gene was notably higher in the TD group than in the sham ($P < 0.01$). While treatment with chrysin with both doses of 30 and 50 mg/kg decreased the expression of the Bax gene in the TDC30 and TDC50 groups compared to the TD group ($P < 0.05$). Expression of the Bcl2 gene in the TD group was lower than in the sham group ($P < 0.01$), while treatment with chrysin in the TDC30 and TDC50 groups significantly increased the expression of the Bcl2 gene ($P < 0.01$) (Table 4). No remarkable differences were found in Bax and Bcl-2 gene expressions in the HC30 and HC50 groups compared to the sham group.

3.4. Testicular Weight and Sperm Parameters. Testicular weight in the TD group significantly decreased compared to the sham group ($P < 0.01$). Treatment with both doses of chrysin (30 and 50 mg/kg) significantly increased the testicular weight compared to the TD group ($P < 0.05$) (Table 5). No significant differences were found in the testicular weight of the HC30 and HC50 groups compared to the sham group. The sperm count in the TD group significantly decreased compared to the sham group ($P < 0.001$), whereas treatment with chrysin in the TDC30 and TDC50 groups significantly increased the sperm count compared to the

TD group ($P < 0.001$). Chrysin treatment with a dose of 30 mg/kg was more effective than 50 mg/kg. Moreover, normal morphology and motility of spermatozoa in the TD group significantly decreased compared to the sham group ($P < 0.001$). Treatment with both doses of chrysin (30 and 50 mg/kg) significantly increased the normal morphology and motility of spermatozoa compared with the TD group ($P < 0.001$) (Table 5).

3.5. Serum LH, FSH, and Testosterone Levels. The serum concentrations of FSH and LH were significantly enhanced in the TD group compared to the sham group ($P < 0.01$), while treatment with chrysin (TDC30 and TDC50 groups) decreased the concentrations of FSH and LH compared to the TD group ($P < 0.05$). 30 mg/kg of chrysin was more effective than 50 mg/kg in decreasing the LH and FSH levels (Table 6). Serum testosterone level in the TD group was significantly lower than in the sham group ($P < 0.01$). Treatment with chrysin in the TDC30 and TDC50 groups meaningfully increased the serum testosterone level ($P < 0.05$). No significant differences were found in serum LH, FSH, and testosterone levels of the HC30 and HC50 groups compared to the sham group.

3.5.1. Expression of Bax and Bcl-2 Proteins in Testicular Tissues Using Immunofluorescence. The immunofluorescence staining assay showed that the expression of Bax protein (Figure 2) was remarkably higher in the testicular section of the TD group than in the sham group. Also, the Bax protein expression was significantly declined in the TD + chrysin group than that of the TD group. On the other hand, no significant difference was noted among the sham and chrysin groups about the Bax expression.

Additionally, the level of Bcl-2 protein (Figure 3) was significantly lower in the TD group than in the sham group. The TD+ chrysin group showed a greater fluorescence intensity for Bcl-2 protein than the TD group. Additionally, no considerable difference was seen between the chrysin and sham groups.

3.5.2. Apoptosis Index in Testis Tissue (TUNEL Assay). The "TUNEL assay" was used to determine how chrysin affected how much the testicular germ cells were apoptosed. As shown in Figure 4, when comparing the testis tissue of the

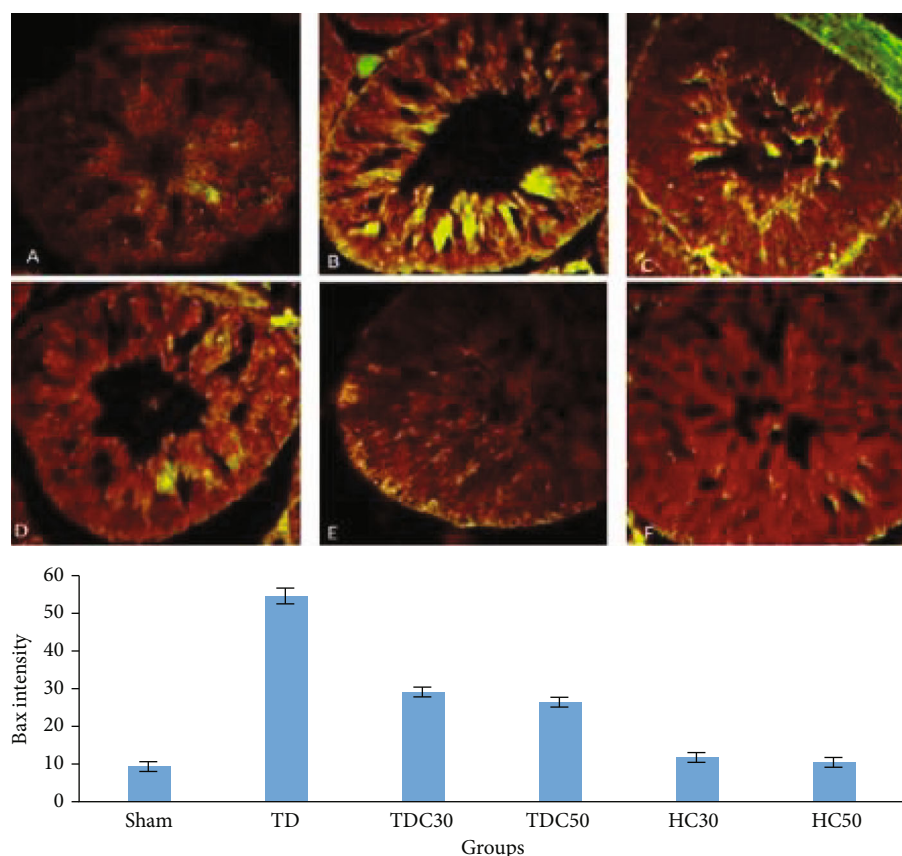


FIGURE 2: Bax protein immunofluorescence staining in the testis of rats in study groups: (A) sham group exhibited normal seminiferous tubules; (B) torsion/detorsion (TD) group; (C) in torsion/detorsion rats that received 30 mg/kg of chrysin (TDC30 group); (D) in torsion/detorsion rats that received 50 mg/kg of chrysin (TDC50 group); (E, F) normal rats that received 30 mg/kg and 50 mg/kg of chrysin (HC30 and HC50 groups) ($\times 400$).

TD group to the sham group, the number of TUNEL-positive cells was significantly ($P = 0.01$) greater in the TD group. Additionally, the current investigation showed that, as compared to the TD group, the number of TUNEL-positive cells in the TD+ chrysin groups significantly ($P = 0.03$) decreased. Furthermore, there was no discernible difference in the quantity of TUNEL-positive cells between the chrysin and sham groups ($P > 0.05$).

4. Discussion

In the current study, we investigated whether chrysin can protect and improve testicular structure and hormonal levels and decrease oxidative stress after torsion/detorsion in male rats. Our results indicated several beneficial effects of chrysin treatment in ischemia/reperfusion injury of the testis, including decreasing the oxidative stress, normalizing the hormonal level, and improving histological parameters (Johnson's score). In this study, torsion/detorsion-induced ischemia/reperfusion injury in testis led to increased oxidative stress by reducing GPx and SOD levels and increasing MDA levels. In agreement with our results, Afolabi et al. show in a study that testicular torsion/detorsion led to increase in MDA level and decrease in SOD, GPx, GSH and GST levels in testicular tissue [24]. Also, the torsion/

detorsion procedure resulted in obvious histopathological damages and reduction of sperm quality. Yazdani et al. show in their study that testicular torsion/detorsion significantly reduced the seminiferous tubule diameter and affected the spermatogenesis and reduction in the mean testicular scores [25], as well as increasing the expression of apoptosis-related genes. Afolabi et al. reported in their study that torsion/detorsion in testis tissue results in overexpression in BAX and cspase-3 in testicular tissue [24]. Recent investigations show that chrysin treatment can improve sperm quality and protect testis against physical and chemical injuries [26].

In our study, testis' weight was decreased in the TD group compared to the sham group. As shown in several studies, testis' torsion/detorsion process leads to significant ROS generation and destructive oxidative damage [27]. Oxidative stress in testis tissue is very detrimental due to highly unsaturated fatty acids [28]. It has been previously demonstrated that ischemia/reperfusion damages in testis tissue resulted in testis atrophy and reduction of testicular weight [29]. Several studies previously reported reduced serum testosterone levels due to testicular torsion/detorsion process [30, 31]. Our results are in agreement with other studies which have reported the reduction of serum testosterone levels in the torsion/detorsion process. Belhan et al. reported in their study that testicular ischemia/reperfusion led to

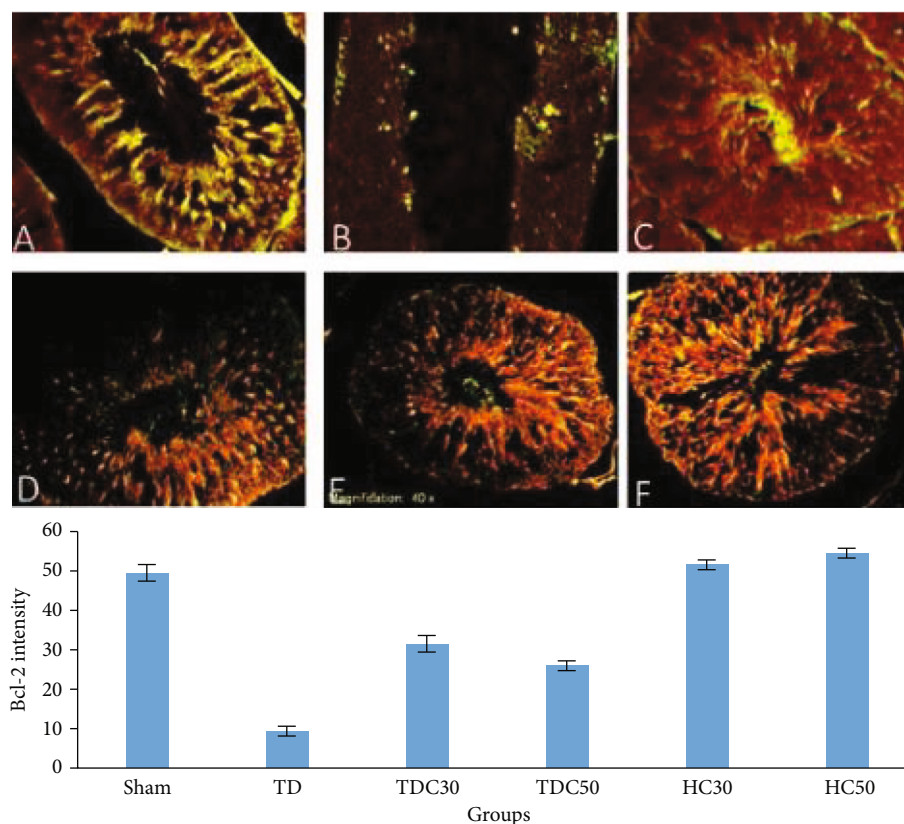


FIGURE 3: Bcl-2 protein immunofluorescence staining in the testis of rats in study groups: (A) sham group exhibited normal seminiferous tubules; (B) torsion/detorsion (TD) group; (C) in torsion/detorsion rats that received 30 mg/kg of chrysin (TDC30 group); (D) in torsion/detorsion rats that received 50 mg/kg of chrysin (TDC50 group); (E, F) normal rats that received 30 mg/kg and 50 mg/kg of chrysin (HC30 and HC50 groups) ($\times 400$).

testis tissue damage and reduction in serum testosterone level [32].

ROS overproduction in ischemia/reperfusion injury first happens after the reperfusion step, which prolongs for a few hours [33]. The second phase of ROS overproduction is seen after reperfusion and prolonged for a few days, depending on the oxidative stress defense system [33]. Furthermore, ROS generation by polymorphonuclear leukocytes in the ischemic region aggravates oxidative damage in tissue [34, 35]. Our results are in agreement with these studies which have reported that testicular I/T led to overproduction of ROS and oxidative stress. In our study, chrysin treatment at both doses of 30 and 50 mg/kg was able to ameliorate oxidative stress in TD rats such as reduced the MDA level and increased the SOD and GPx levels. Some on research show that the treatment with chrysin can reduced the oxidative stress using its antioxidant properties [36, 37]. The current research indicated that the torsion/detorsion process led to the elevation of MDA level as a marker of lipid peroxidation, which is in accordance with previous studies [33]. Moreover, SOD and GPx levels meaningfully decreased in the TD group which is in accordance with other investigations [38, 39].

Additionally, excessive ROS generation or oxidative stress might activate the intrinsic apoptosis pathway, which is controlled by two sets of antiapoptotic proteins (such as

BAX, Bad, and Bid). It initiates the apoptotic pathway and suppresses antiapoptosis proteins (including Bcl-2 and Bcl-xl). According to a study by Shokoohi et al., Bax family expression is increased by oxidative stress brought on by the formation of ROS [40].

In our research, the apoptosis rate of the germinal cell was assessed by the real-time PCR, immunofluorescence, and TUNEL assay. This study showed that the TD group's Bax mRNA expression was noticeably higher than that of the control group. Contrarily, the Bcl-2 expression was remarkably declined in the TD group. Also, our results show that testicular torsion/detorsion led to reduction in sperm quality such as decrease in sperm count, motility, and normal morphology. In agreement with our results, Ameli et al. reported in their research that testicular I/R led to reduction in sperm quality in rats with testicular torsion/detorsion [41].

Chrysin is a well-known flavonoid usually found in honey, mushrooms, and some plant species [42]. Recent investigations have suggested several pharmaceutical effects of chrysin, such as antioxidant, anticancer, anti-inflammatory, neuroprotective, and cardioprotective properties [43, 44]. As reported in many recent studies, chrysin indicated various beneficial effects on reproductive disorders in both males and females [21]. Previously, chrysin indicated protective effects against methotrexate-induced testicular damages

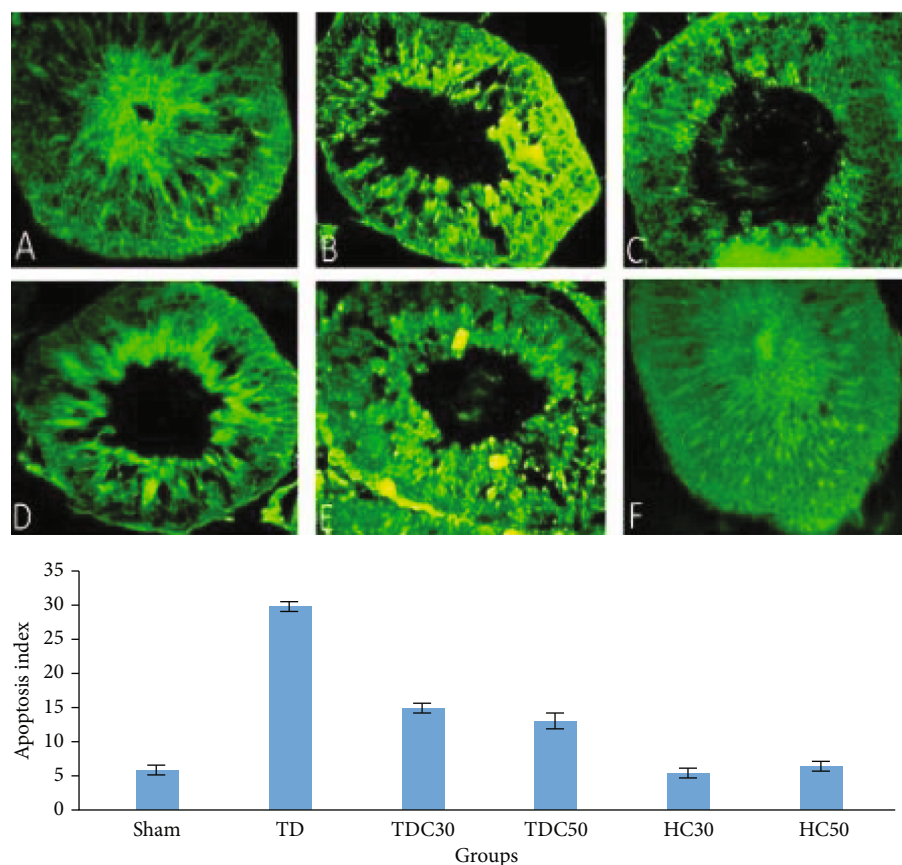


FIGURE 4: The representative image of TUNEL-positive cells in testicular tissue: (A) sham group exhibited normal seminiferous tubules; (B) torsion/detorsion (TD) group; (C) in torsion/detorsion rats that received 30 mg/kg of chrysin (TDC30 group); (D) in torsion/detorsion rats that received 50 mg/kg of chrysin (TDC50 group); (E, F) normal rats that received 30 mg/kg and 50 mg/kg of chrysin (HC30 and HC50 groups) ($\times 400$).

through improving antioxidant defense, sperm quality, and histological parameters [45]. One independent study evaluated the effects of chrysin against ovary ischemia/reperfusion injury induced by the torsion/detorsion process [46]. Melkoglu et al. show in a study that chrysin administration (50 mg/kg) in rats with ovarian torsion/detorsion process significantly reduced oxidative stress markers and improved histopathological scores of ovaries as well as normalizing hormonal levels [46]. Also, Cho et al. reported in a study that chrysin's inhibitory effects on the expression of inducible nitric oxide synthase and cyclooxygenase-2 are what account for the substance's antioxidative properties [47]. Chrysin may provide antioxidant and free radical scavenging properties in testis tissue, as well as prevent lipid peroxidation, according to a number of recent research. These results are consistent with our observations [48, 49].

In agreement with our study, in both *in vitro* and *in vivo* studies, chrysin treatment increased testosterone production from the Leydig cells [50]. In a recent survey, interestingly, sperm motility, concentration, and aberrant sperm rate were all enhanced by chrysin treatment at a 50 mg/kg dose in normal rats [20, 50]. Based on our results, chrysin treatment with 30 mg/kg dose demonstrated a better protective effect against ischemia/reperfusion injury. It indicated better improvement in sperm quality compared to the 50 mg/kg

administration of chrysin. Darwish et al. used chrysin in 25 and 50 mg/kg doses to alleviate testicular damages in adjuvant arthritic rats [51]. They have found that chrysin with the dose of 50 mg/kg had stronger protective effects against testicular dysfunction of adjuvant arthritic rats through increasing testosterone levels and decreasing testicular oxidative stress and apoptosis [51]. This disagreement could be attributed to the induced model of testicular damage. Additionally, chrysin treatment in colistin-induced testicular damages significantly decreased apoptotic and autophagic-related genes such as caspase-3 and LC3B, as well as reduced oxidative stress markers [48]. Also, oral administration of chrysin in a 40-week-old male rooster significantly improved the postthawed and fresh sperm motility and plasma membrane integrity [52, 53].

5. Conclusion

Herein, we have found that in testicular torsion/detorsion rat's spermatogenesis, sperm quality, testis histological structure, and hormonal levels significantly declined compared with normal rats. Chrysin in both dosages ameliorated the detrimental effect of TD on mentioned parameters. Chrysin with a 30 mg/kg dose had better therapeutic effects on ameliorating the TD-induced damages. The current work

concluded that chrysin could protect testis tissue and spermatogenesis quality against the TD process via indicating antioxidative effects, antiapoptotic properties, and hormonal regulations.

Data Availability

The data that support the findings of this study are available from the corresponding authors upon reasonable request.

Conflicts of Interest

The authors declare that they have no conflict of interest.

Authors' Contributions

Amir Afshin Khaki, Homa Mohseni Kouchesfahani, and Ayda Roudi Rashr Abadi planned and designed the experiments. Majid Shokoohi performed the experiments. Majid Shokoohi and Ayda Roudi Rashr Abadi analyzed the data. Amir Afshin Khaki, Homa Mohseni Kouchesfahani, Ayda Roudi Rashr Abadi, Majid Shokoohi, Linda Mohammadzadeh, and Monireh Mahmoodi wrote the manuscript.

Acknowledgments

The authors would like to express their gratitude to the Department of Animal Biology, Faculty of Biological Sciences, Kharazmi University, Tehran, Iran, for their support. And we would like to thank the Clinical Research Development Unit of Tabriz Valiasr Hospital, Tabriz University of Medical Sciences, Tabriz, Iran, for their assistance in this research.

References

- [1] R. J. Aitken, G. N. De Iulii, and J. R. Drevet, "Role of oxidative stress in the etiology of male infertility and the potential therapeutic value of antioxidants," in *Oxidants, Antioxidants and Impact of the Oxidative Status in Male Reproduction*, pp. 91–100, Elsevier, 2019.
- [2] B. B. Mohanty, D. Agrawal, K. Mishra, P. Samantsinghar, and P. K. Chinara, "Estimation of height of an individual from forearm length on the population of Eastern India," *Journal of Medical & Allied Sciences*, vol. 3, no. 2, p. 72, 2013.
- [3] A. Oliva, A. Spira, and L. Multigner, "Contribution of environmental factors to the risk of male infertility," *Human Reproduction*, vol. 16, no. 8, pp. 1768–1776, 2001.
- [4] M.-H. Lin, R. K.-K. Lee, S.-H. Li, C.-H. Lu, F.-J. Sun, and Y.-M. Hwu, "Sperm chromatin structure assay parameters are not related to fertilization rates, embryo quality, and pregnancy rates in in vitro fertilization and intracytoplasmic sperm injection, but might be related to spontaneous abortion rates," *Fertility and Sterility*, vol. 90, no. 2, pp. 352–359, 2008.
- [5] M. F. Elshal, I. H. El-Sayed, M. A. Elsaied, S. A. El-Masry, and T. A. Kumosani, "Sperm head defects and disturbances in spermatozoal chromatin and DNA integrities in idiopathic infertile subjects: association with cigarette smoking," *Clinical Biochemistry*, vol. 42, no. 7-8, pp. 589–594, 2009.
- [6] K.-K. Chi, W.-H. Zhang, G.-C. Wang et al., "Comparison of intraperitoneal and intraepididymal quercetin for the prevention of testicular torsion/detorsion-induced injury," *Urology*, vol. 99, pp. 106–111, 2017.
- [7] I. D. Kostakis, N. Zavras, C. Damaskos et al., "Erythropoietin and sildenafil protect against ischemia/reperfusion injury following testicular torsion in adult rats," *Experimental and Therapeutic Medicine*, vol. 13, no. 6, pp. 3341–3347, 2017.
- [8] M. Mirhoseini, F. T. Amiri, A. A. K. Malekshah, Z. R. Gatabi, and E. Ghaffari, "Protective effects of melatonin on testis histology following acute torsion-detorsion in rats," *International Journal of Reproductive Biomedicine*, vol. 15, no. 3, pp. 141–146, 2017.
- [9] F. R. Romero, R. P. X. Gomes, F. Lorenzini, T. R. Erdmann, and R. Tambara Filho, "Ipsilateral testicular necrosis and atrophy after 1,080-degree torsion of the spermatic cord in rats," *Acta Cirurgica Brasileira*, vol. 24, no. 2, pp. 118–123, 2009.
- [10] T. E. Şener, M. Yüksel, N. Özyılmaz-Yay et al., "Apocynin attenuates testicular ischemia-reperfusion injury in rats," *Journal of Pediatric Surgery*, vol. 50, no. 8, pp. 1382–1387, 2015.
- [11] B. S. Parlaktas, D. Atilgan, H. Ozyurt et al., "The biochemical effects of ischemia-reperfusion injury in the ipsilateral and contralateral testes of rats and the protective role of melatonin," *Asian Journal of Andrology*, vol. 16, no. 2, pp. 314–318, 2014.
- [12] M. Schieber and N. S. Chandel, "ROS function in redox signaling and oxidative stress," *Current Biology*, vol. 24, no. 10, pp. R453–R462, 2014.
- [13] A. Agarwal, R. A. Saleh, and M. A. Bedaiwy, "Role of reactive oxygen species in the pathophysiology of human reproduction," *Fertility and Sterility*, vol. 79, no. 4, pp. 829–843, 2003.
- [14] D. Sanocka and M. Kurpisz, "Reactive oxygen species and sperm cells," *Reproductive Biology and Endocrinology*, vol. 2, no. 1, p. 12, 2004.
- [15] J. Twigg, N. Fulton, E. Gomez, D. S. Irvine, and R. J. Aitken, "Analysis of the impact of intracellular reactive oxygen species generation on the structural and functional integrity of human spermatozoa: lipid peroxidation, DNA fragmentation and effectiveness of antioxidants," *Human Reproduction (Oxford, England)*, vol. 13, no. 6, pp. 1429–1436, 1998.
- [16] V. C. George, G. Delleire, and H. P. V. Rupasinghe, "Plant flavonoids in cancer chemoprevention: role in genome stability," *The Journal of Nutritional Biochemistry*, vol. 45, pp. 1–14, 2017.
- [17] M. Zeinali, S. A. Rezaee, and H. Hosseinzadeh, "An overview on immunoregulatory and anti-inflammatory properties of chrysin and flavonoids substances," *Biomedicine & Pharmacotherapy*, vol. 92, pp. 998–1009, 2017.
- [18] E. R. Kasala, L. N. Bodduluru, C. C. Barua et al., "Chemopreventive effect of chrysin, a dietary flavone against benzo(a)pyrene induced lung carcinogenesis in Swiss albino mice," *Pharmacological Reports*, vol. 68, no. 2, pp. 310–318, 2016.
- [19] Z.-Y. Zhu, Y. Luo, Y. Liu et al., "Inclusion of chrysin in β -cyclodextrin and its biological activities," *Journal of Drug Delivery Science and Technology*, vol. 31, pp. 176–186, 2016.
- [20] O. Ciftci, İ. Ozdemir, M. Aydin, and A. Beytur, "Beneficial effects of chrysin on the reproductive system of adult male rats," *Andrologia*, vol. 44, no. 3, pp. 181–186, 2012.
- [21] E. Aksu, M. Özkaraca, F. Kandemir et al., "Mitigation of paracetamol-induced reproductive damage by chrysin in male rats via reducing oxidative stress," *Andrologia*, vol. 48, no. 10, pp. 1145–1154, 2016.
- [22] H. Shoorei, A. Khaki, A. A. Khaki, A. A. Hemmati, M. Moghimian, and M. Shokoohi, "The ameliorative effect of

- carvacrol on oxidative stress and germ cell apoptosis in testicular tissue of adult diabetic rats," *Biomedicine & Pharmacotherapy*, vol. 111, pp. 568–578, 2019.
- [23] T. T. Turner and J. J. Lysiak, "Oxidative stress: a common factor in testicular dysfunction," *Journal of Andrology*, vol. 29, no. 5, pp. 488–498, 2008.
- [24] O. Afolabi, B. Alabi, T. Omobowale, O. Oluranti, and O. Iwalewa, "Cysteamine mitigates torsion/detorsion-induced reperfusion injury via inhibition of apoptosis, oxidative stress and inflammatory responses in experimental rat model," *Andrologia*, vol. 54, no. 1, article e14243, 2022.
- [25] I. Yazdani, R. Majdani, M. Ghasemnejad-berenji, and A. R. Dehpour, "Beneficial effects of cyclosporine A in combination with nortriptyline on germ cell-specific apoptosis, oxidative stress and epididymal sperm qualities following testicular ischemia/reperfusion in rats: a comparative study," *BMC Pharmacology and Toxicology*, vol. 23, no. 1, p. 59, 2022.
- [26] G. Missassi, C. dos Santos Borges, J. de Lima Rosa et al., "Chrysin administration protects against oxidative damage in varicocele-induced adult rats," *Oxidative Medicine and Cellular Longevity*, vol. 2017, Article ID 2172981, 12 pages, 2017.
- [27] M. Moghimian, M. Soltani, H. Abtahi, J. Adabi, and N. Jajarmy, "Protective effect of tunica albuginea incision with tunica vaginalis flap coverage on tissue damage and oxidative stress following testicular torsion: role of duration of ischemia," *Journal of Pediatric Urology*, vol. 12, no. 6, pp. 390.e1–390.e6, 2016.
- [28] R. J. Aitken and S. D. Roman, "Antioxidant systems and oxidative stress in the testes," *Oxidative Medicine and Cellular Longevity*, vol. 1, no. 1, Article ID 616821, 24 pages, 2008.
- [29] C.-J. Yu, J. Zhao, J. Luo et al., "Long-term follow-up results of testicular torsion in children," *Asian Journal of Andrology*, vol. 24, no. 6, pp. 653–659, 2022.
- [30] M. Kanter, "Protective effects of melatonin on testicular torsion/detorsion-induced ischemia-reperfusion injury in rats," *Experimental and Molecular Pathology*, vol. 89, no. 3, pp. 314–320, 2010.
- [31] M. Soltani, M. Moghimian, S. H. Abtahi-Eivari, H. Shoorei, A. Khaki, and M. Shokoohi, "Protective effects of *Matricaria chamomilla* extract on torsion/detorsion-induced tissue damage and oxidative stress in adult rat testis," *International Journal of Fertility & Sterility*, vol. 12, no. 3, pp. 242–248, 2018.
- [32] S. Belhan, S. Yildirim, C. Kayikci, A. U. Kömüroğlu, U. Özdek, and Y. Kuşçu, "Investigation of the effect of silymarin on oxidative DNA damage and inflammatory markers in ischemia/reperfusion injury following experimental testicular torsion/detorsion in rats," *Turkish Journal of Zoology*, vol. 45, no. 4, pp. 267–276, 2021.
- [33] S. A. Abdel-Gaber, R. K. Mohammed, and M. M. M. Refaie, "Mechanism mediating the protective effect of diacerein in ischemia-reperfusion-induced testicular injury in rats," *Life Sciences*, vol. 209, pp. 57–62, 2018.
- [34] K. J. Dery and J. W. Kupiec-Weglinski, "New insights into ischemia-reperfusion injury signaling pathways in organ transplantation," *Current Opinion in Organ Transplantation*, vol. 27, no. 5, pp. 424–433, 2022.
- [35] H. Olmez, M. Tosun, E. Unver et al., "The role of polymorphonuclear leukocytes in distant organ (lung) oxidative damage of liver ischemia/reperfusion and the protective effect of rutin," *Advances in Clinical and Experimental Medicine*, vol. 32, no. 1, pp. 81–89, 2022.
- [36] X. Li, X. Li, and L. Deng, "Chrysin reduces inflammation and oxidative stress and improves ovarian function in D-gal-induced premature ovarian failure," *Bioengineered*, vol. 13, no. 4, pp. 8291–8301, 2022.
- [37] M. M. Soliman, A. Aldhahrani, A. Gaber et al., "Ameliorative impacts of chrysin against gibberellic acid-induced liver and kidney damage through the regulation of antioxidants, oxidative stress, inflammatory cytokines, and apoptosis biomarkers," *Toxicology Research*, vol. 11, no. 1, pp. 235–244, 2022.
- [38] A. Beheshtian, A. H. Salmasi, S. Payabvash et al., "Protective effects of sildenafil administration on testicular torsion/detorsion damage in rats," *World Journal of Urology*, vol. 26, no. 2, pp. 197–202, 2008.
- [39] A. H. Salmasi, A. Beheshtian, S. Payabvash et al., "Effect of morphine on ischemia-reperfusion injury: experimental study in testicular torsion rat model," *Urology*, vol. 66, no. 6, pp. 1338–1342, 2005.
- [40] M. Shokoohi, A. Khaki, A. Roudi Rasht Abadi et al., "Minocycline can reduce testicular apoptosis related to varicocele in male rats," *Andrologia*, vol. 54, no. 4, article e14375, 2022.
- [41] M. Ameli, M. S. Hashemi, M. Moghimian, and M. Shokoohi, "Protective effect of tadalafil and verapamil on testicular function and oxidative stress after torsion/detorsion in adult male rat," *Andrologia*, vol. 50, no. 8, article e13068, 2018.
- [42] S. F. Nabavi, N. Braidy, S. Habtemariam et al., "Neuroprotective effects of chrysin: from chemistry to medicine," *Neurochemistry International*, vol. 90, pp. 224–231, 2015.
- [43] E. R. Kasala, L. N. Bodduluru, C. C. Barua, and R. Gogoi, "Chrysin and its emerging role in cancer drug resistance," *Chemico-Biological Interactions*, vol. 236, pp. 7–8, 2015.
- [44] J. Sathivelu, G. J. Senapathy, R. Devaraj, and N. Namasivayam, "Hepatoprotective effect of chrysin on prooxidant-antioxidant status during ethanol-induced toxicity in female albino rats," *Journal of Pharmacy and Pharmacology*, vol. 61, no. 6, pp. 809–817, 2009.
- [45] S. Belhan, S. Çomaklı, S. Küçükler, F. Gülyüz, S. Yıldırım, and Z. Yener, "Effect of chrysin on methotrexate-induced testicular damage in rats," *Andrologia*, vol. 51, no. 1, article e13145, 2019.
- [46] R. Melekoglu, O. Ciftci, S. Eraslan, S. Alan, and N. Basak, "The Protective Effects of Glycyrrhetic Acid and Chrysin against Ischemia-Reperfusion Injury in Rat Ovaries," *BioMed Research International*, vol. 2018, Article ID 5421308, 7 pages, 2018.
- [47] H. Cho, C.-W. Yun, W.-K. Park et al., "Modulation of the activity of pro-inflammatory enzymes, COX-2 and iNOS, by chrysin derivatives," *Pharmacological Research*, vol. 49, no. 1, pp. 37–43, 2004.
- [48] E. H. Aksu, F. M. Kandemir, S. Küçükler, and A. Mahamad, "Improvement in colistin-induced reproductive damage, apoptosis, and autophagy in testes via reducing oxidative stress by chrysin," *Journal of Biochemical and Molecular Toxicology*, vol. 32, no. 11, article e22201, 2018.
- [49] A. E. El-Sisi, M. E. El-Sayad, and N. M. Abdelsalam, "Protective effects of mirtazapine and chrysin on experimentally induced testicular damage in rats," *Biomedicine & Pharmacotherapy*, vol. 95, pp. 1059–1066, 2017.
- [50] M. M. Soliman, A. Aldhahrani, H. I. Ghamry et al., "Chrysin abrogates gibberellic acid-induced testicular oxidative stress and dysfunction via the regulation of antioxidants and steroidogenesis- and apoptosis-associated genes," *Journal of Food Biochemistry*, vol. 46, no. 8, article e14165, 2022.

- [51] H. A. Darwish, H. H. Arab, and R. M. Abdelsalam, "Chrysin alleviates testicular dysfunction in adjuvant arthritic rats via suppression of inflammation and apoptosis: comparison with celecoxib," *Toxicology and Applied Pharmacology*, vol. 279, no. 2, pp. 129–140, 2014.
- [52] A. S. A. Altawash, A. Z. Shahneh, H. Moravej, and M. Ansari, "Chrysin-induced sperm parameters and fatty acid profile changes improve reproductive performance of roosters," *Theriogenology*, vol. 104, pp. 72–79, 2017.
- [53] M. Zhandi, M. Ansari, P. Roknabadi, A. Zare Shahneh, and M. Sharafi, "Orally administered chrysin improves post-thawed sperm quality and fertility of rooster," *Reproduction in Domestic Animals*, vol. 52, no. 6, pp. 1004–1010, 2017.